Subintimal Angioplasty of Tibial Arteries for Limb Salvage

Peter A. Schneider, MD

Honolulu, Hawaii

Conflicts of interest

- Advisory Board: AbbottVascular
- Educational Programs: Medtronic
- Royalties: Cook

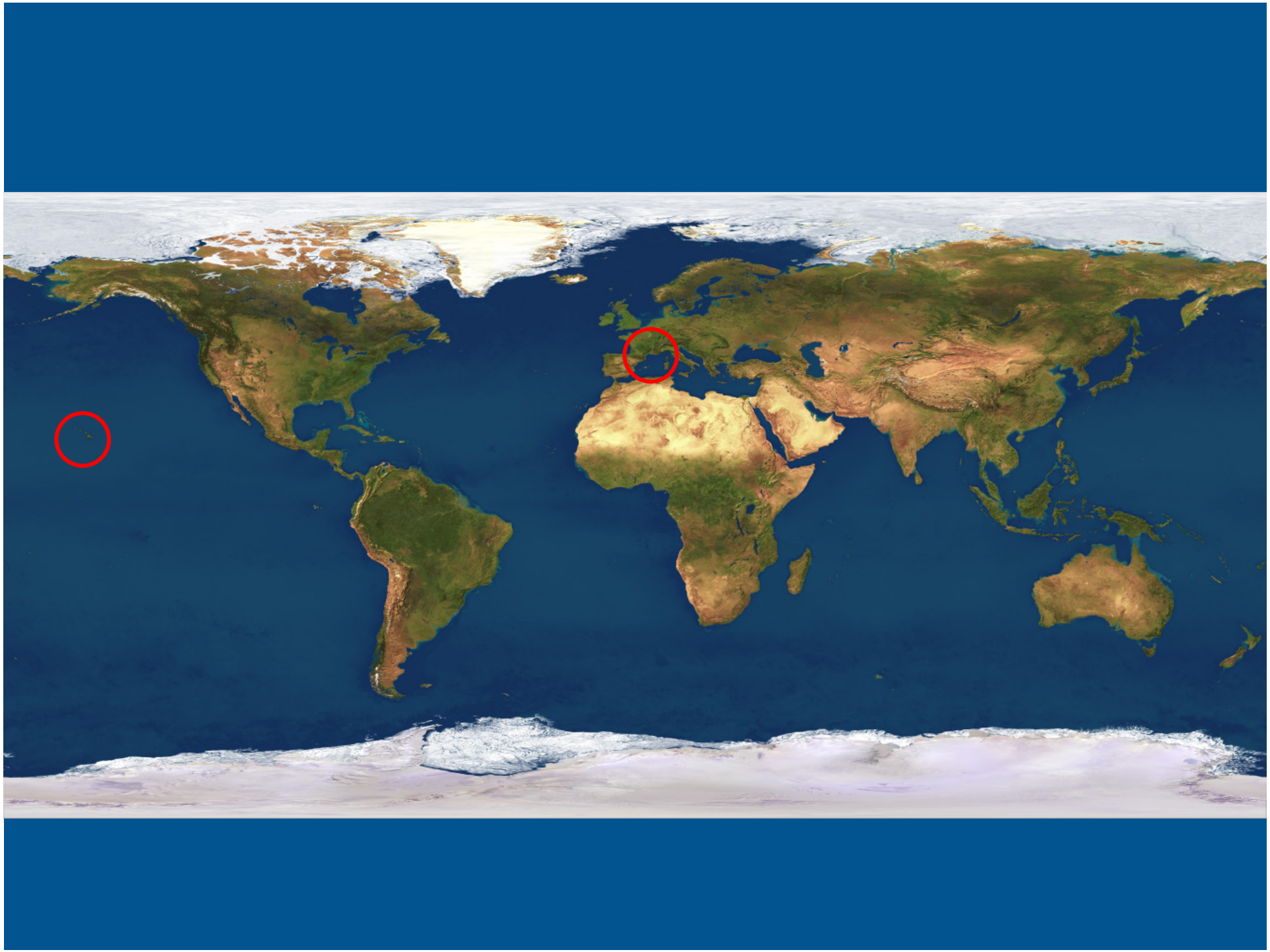

GRAND CRU CLASSÉ
Château Pavie
ST-ÉMILION GRAND CRU
1990
VALETTE
1998
CHÂTEAU GAZIN
POMEROL

WE NEED A
FEW FREE MINDS

Distal bypass evolved over a period of 25 years.

Endovascular management of tibial occlusions is in an early stage of evolution.

1) Place the tip of the sheath as close to the target lesion as possible.

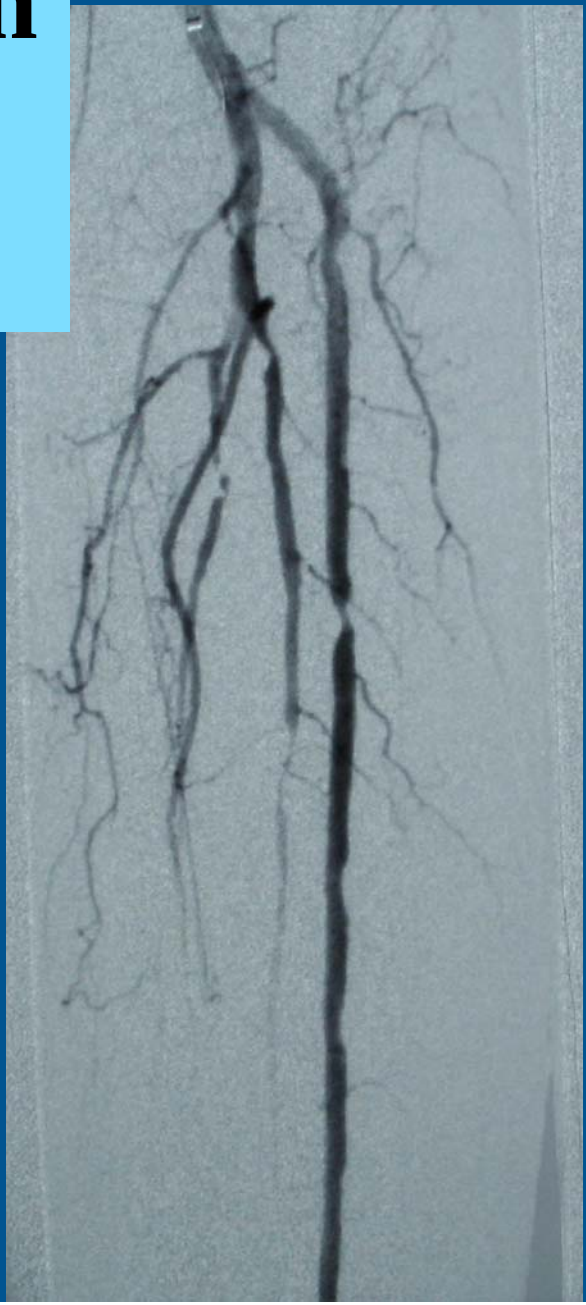

Place the tip of the sheath as close to the target lesion as possible.

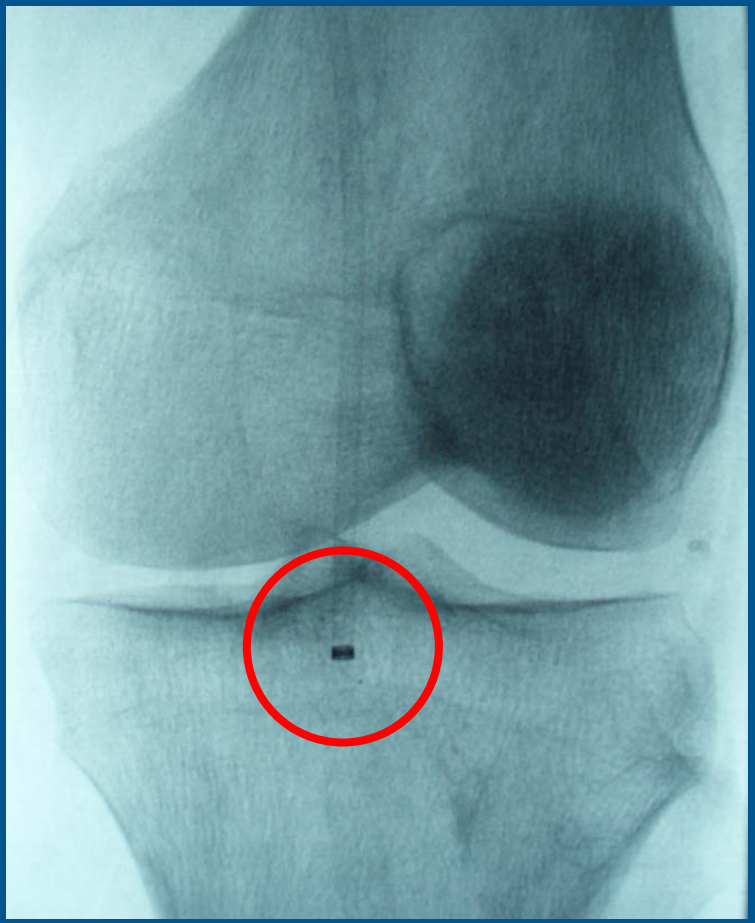

Sheath



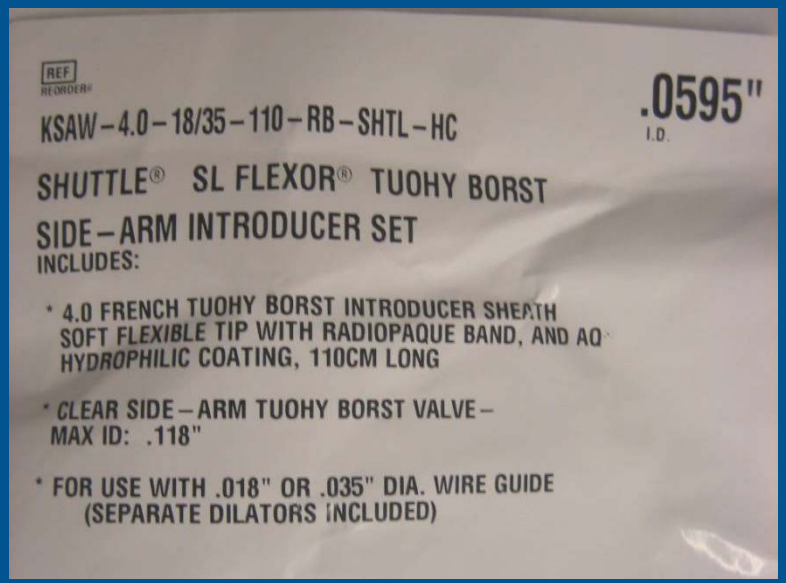

Better control
Less contrast
Less radiation

2) Measure distance to target lesion: this helps with approach, choice of sheath, availability of equipment.

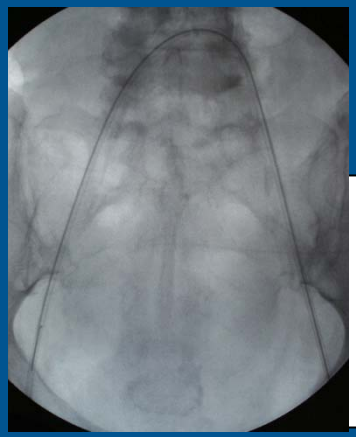

Prefer contralateral approach

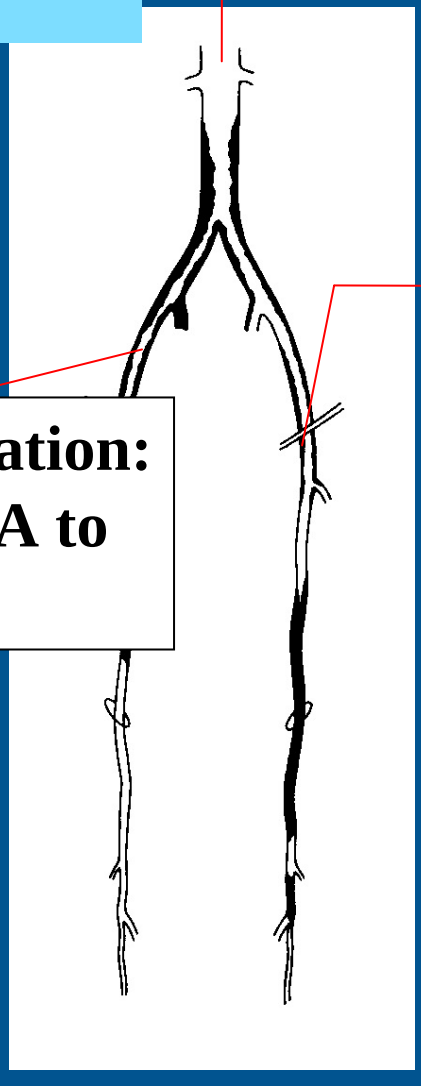

Over the bifurcation: 90 cm-distal SFA to distal popliteal

Brachial approach: 90 cm-distal aorta to distal iliac

Antegrade approach: 60 cm to tibial



3) Use 014 platform, monorail when available

- Less friction
- Faster
- Lower profile
- Guidewire stability
- Cool stuff

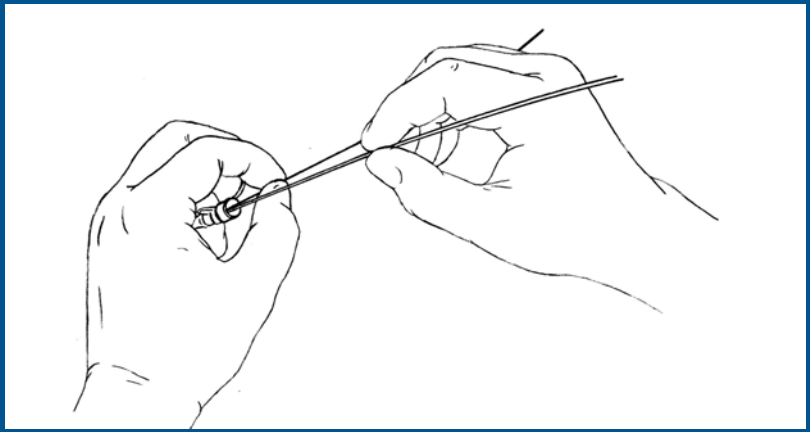

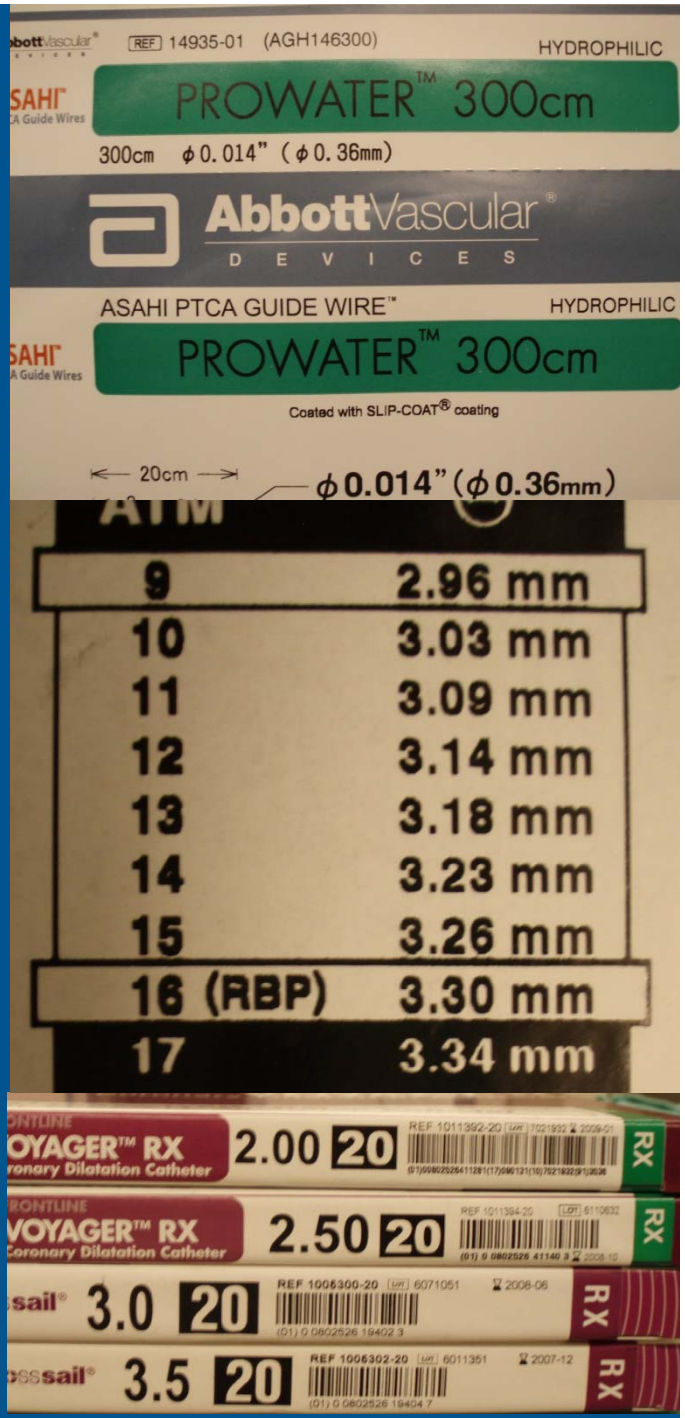

PROWATER 300cm
Abbott Vascular
ASAHI PTCA GUIDE WIRE
PROWATER 300cm
Straight
300cm
CAUTION

TERUMO
RADIFOCUS
GLIDECATH
Angiographic Catheter with Hydrophilic Coating M
Cathéter d' Angiographie avec Revêtement Hydrophile M
Angiographie-Katheter mit hydrophiler Oberflächenvergütung M
Catéter Angiográfico con Recubrimiento Hidrofílico M
Catetere Angiografico con Rivestimento Idrofilico M
Angiografie Catheter met Hydrofiel Oppervlak M
Angiografisk Kateter med Hydrofil Belägging M
Cateter angiográfico com revestimento hidrofílico M
Non-taper Angle
GUIDE WIRE DIAMETER: GUIDE DIAMETRE:
FUHRUNGSDRAHT: DIAMETRO GUIA:
DIAMETRO DELLA GUIDA: VOERDRAADDIAMETER:
GUIDE WIRE DIAMETER: DIÂMETRO DO FIO-GUIA:
.038" (0.97 mm)
Fr. 4
(1.40 mm)
TIP CURVE LENGTH: EXTREMITE COURBE LONGUEUR: KURVENLÄNGE:



4) Get across the occlusion:

Use a firm, low profile guidewire and a microcatheter with a stiff tip.

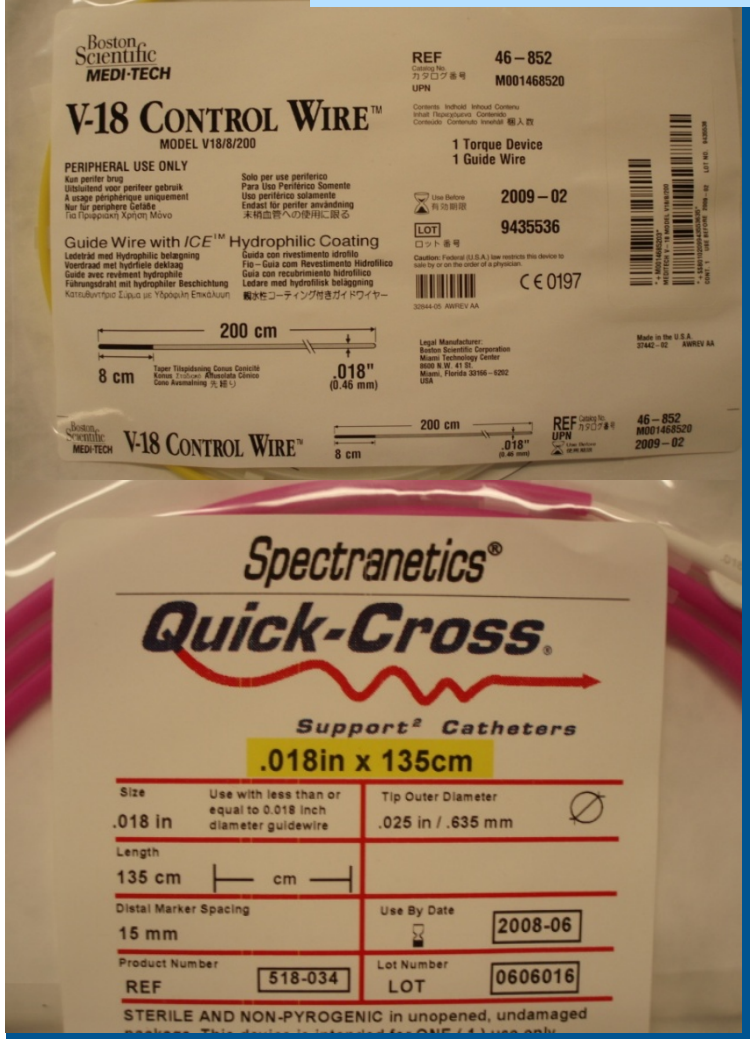

PT
AT

Spectranetics®
Quick-Cross®
Support² Catheters
.014in x 135cm
Size
.014 in
Use with less than or equal to 0.014 inch diameter guidewire
Tip Outer Diameter
.021 in / .533 mm
Length
135 cm
cm
Distal Marker Spacing
15 mm
Use By Date
2008-05

Laser: heavily calcified lesions, those that cannot be crossed with guidewire.

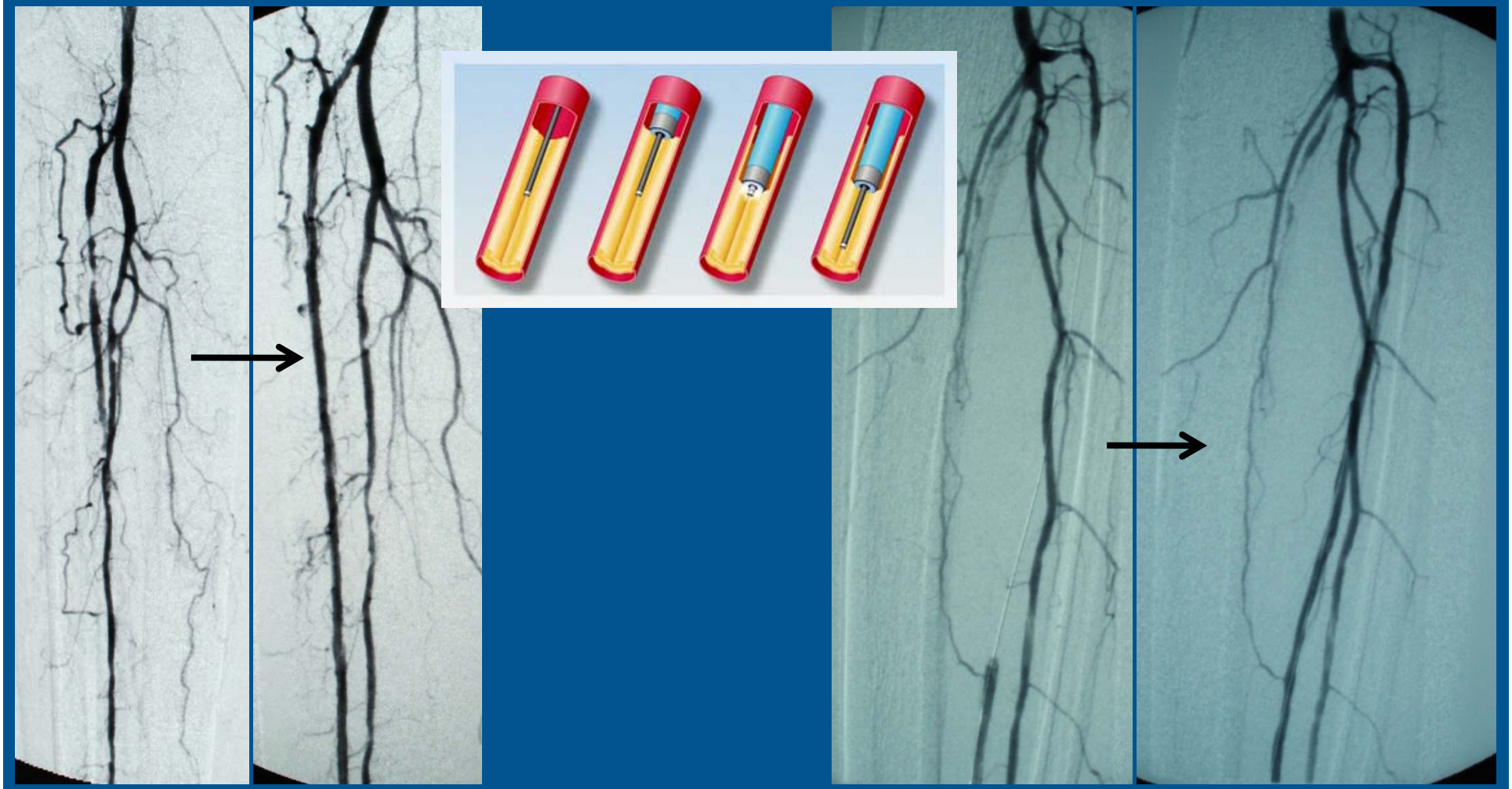

5) After crossing the occlusion, use a balloon that covers the whole length of the lesion.

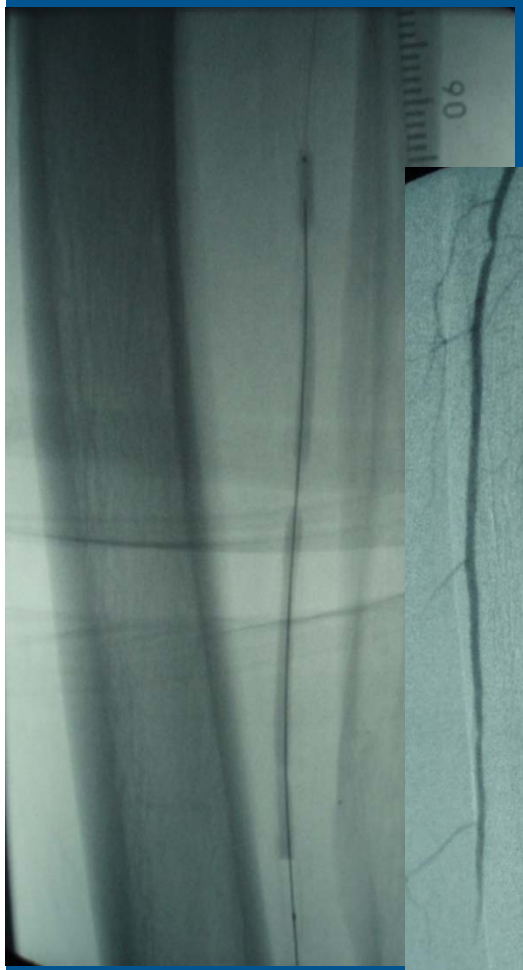

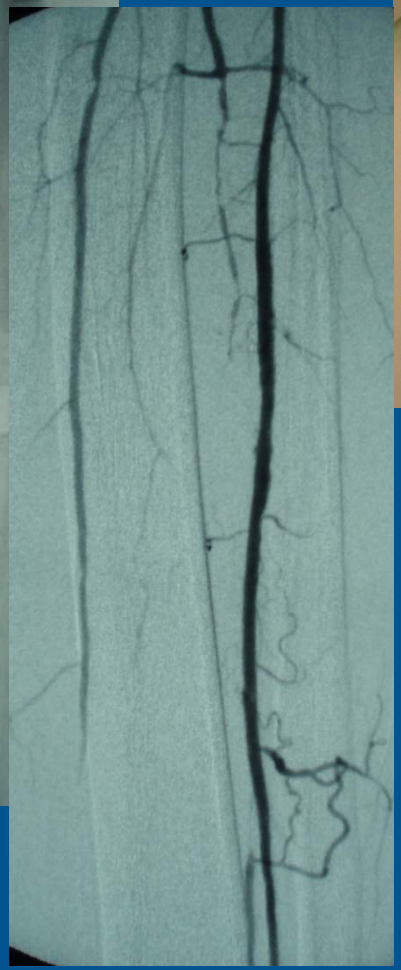

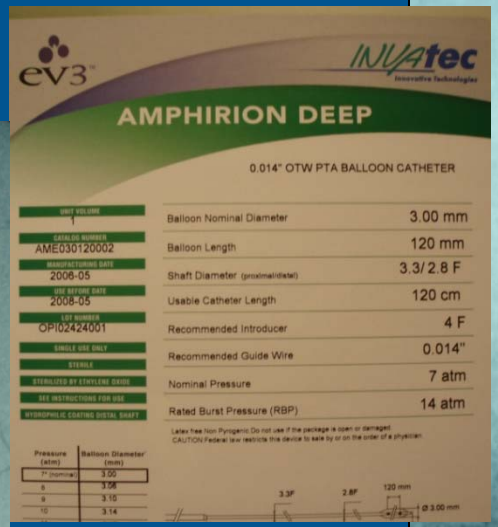

014 guidewire in dorsalis pedis

6) Use stents sparingly.



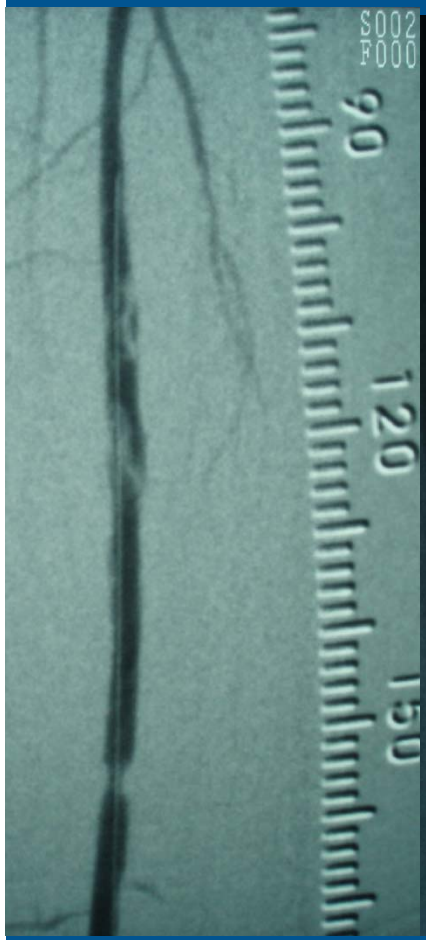

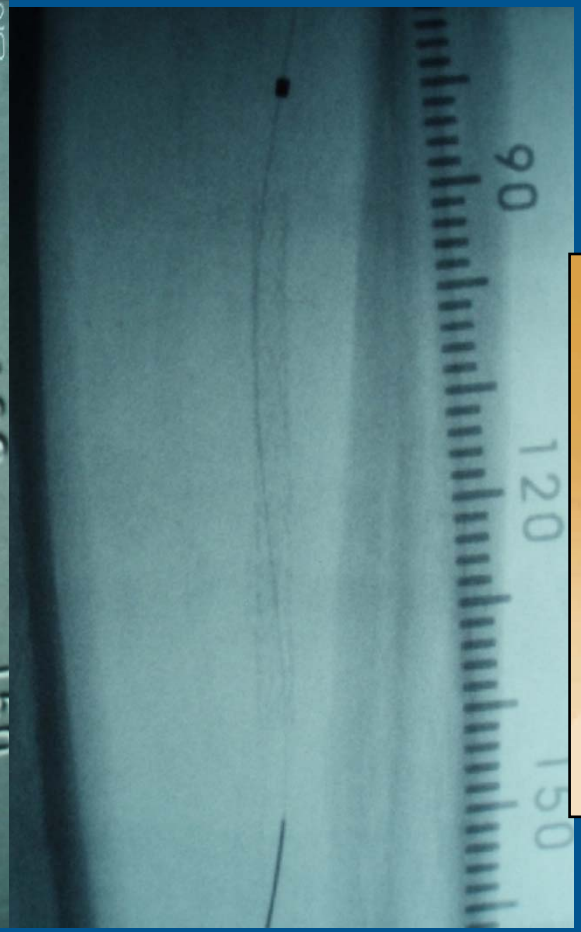



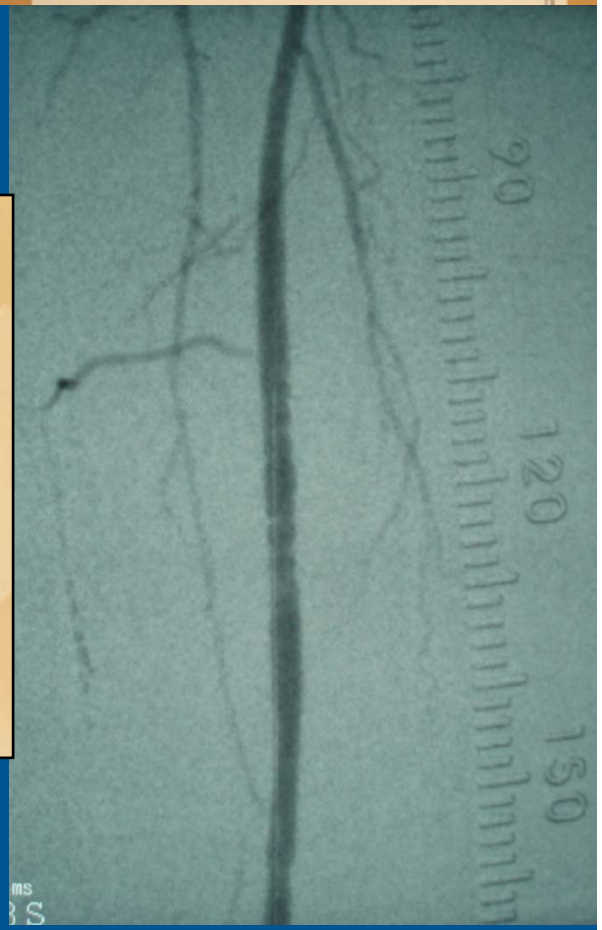

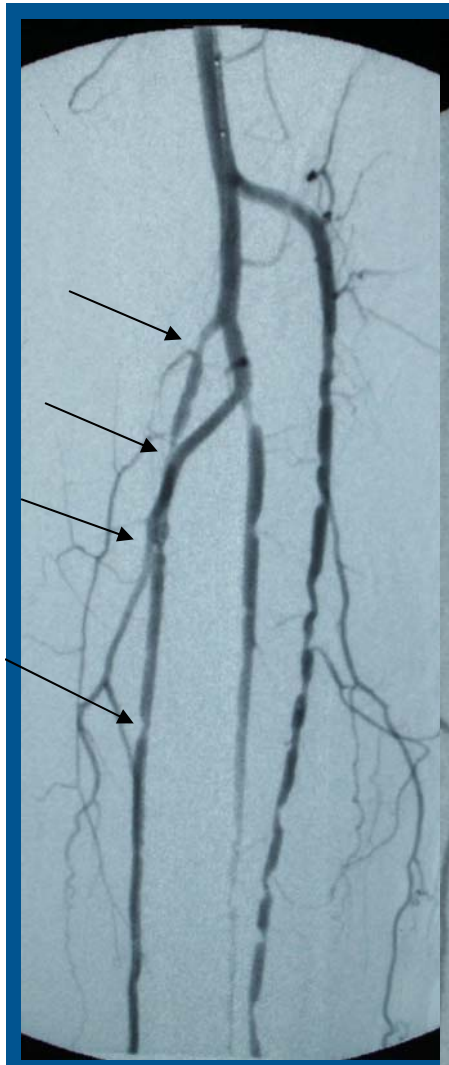

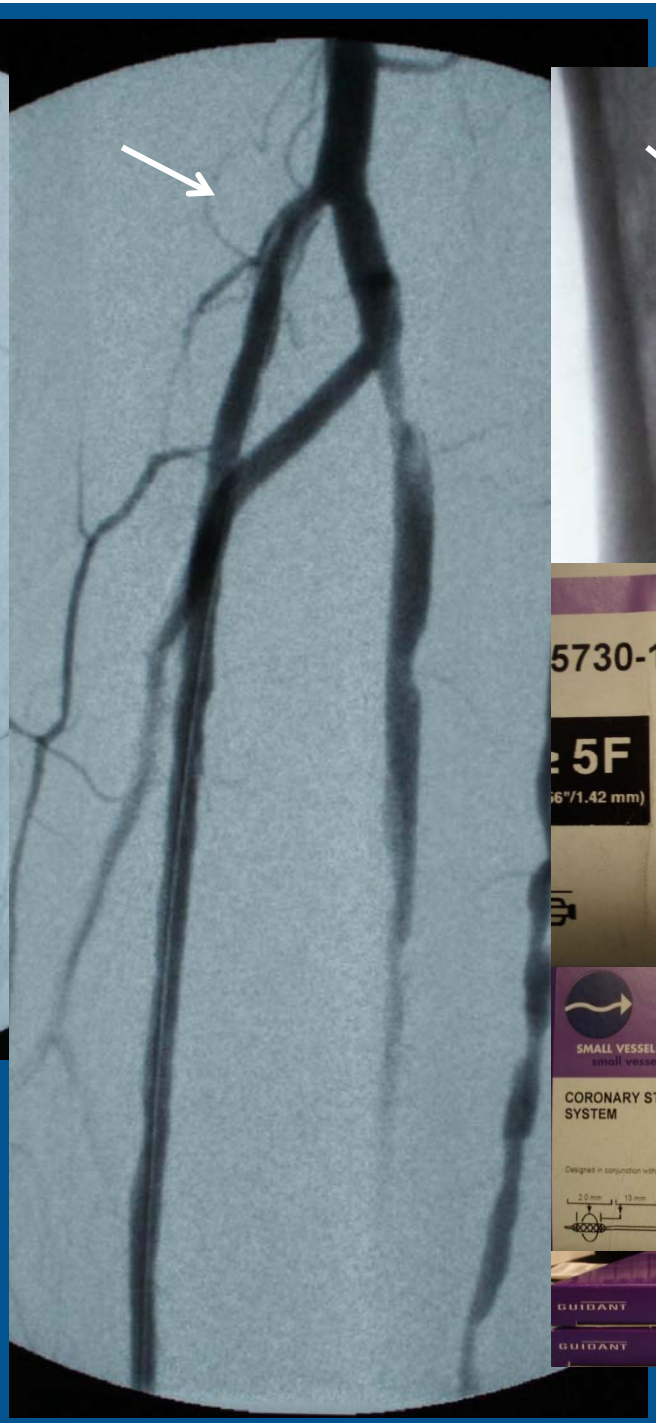

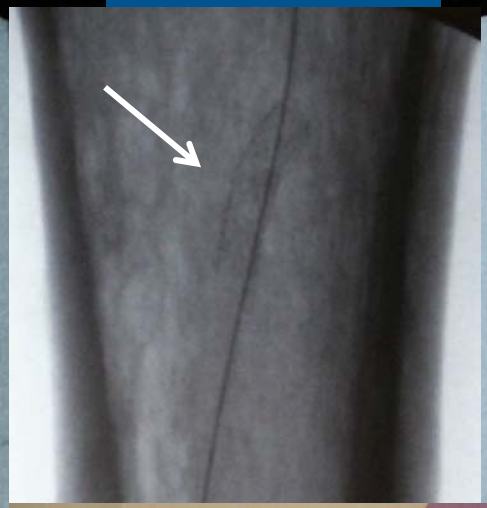

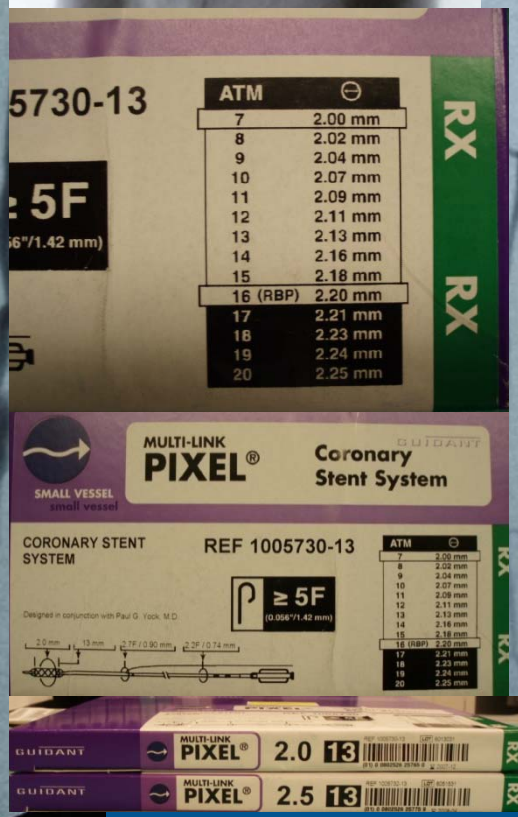
5730-13
ATM
7 2.00 mm
8 2.02 mm
9 2.04 mm
10 2.07 mm
11 2.09 mm
12 2.11 mm
13 2.13 mm
14 2.16 mm
15 2.18 mm
16 (RBP) 2.20 mm
17 2.21 mm
18 2.23 mm
19 2.24 mm
20 2.25 mm
RX
RX
≥ 5F
(0.056"/1.42 mm)
SMALL VESSEL
small vessel
MULTI-LINK
PIXEL®
Coronary
Stent System
GUIDANT
CORONARY STENT
SYSTEM
REF 1005730-13
≥ 5F
(0.056"/1.42 mm)

GUIDANT
MULTI-LINK
PIXEL®
2.0
13
GUIDANT
MULTI-LINK
PIXEL®
2.5
13

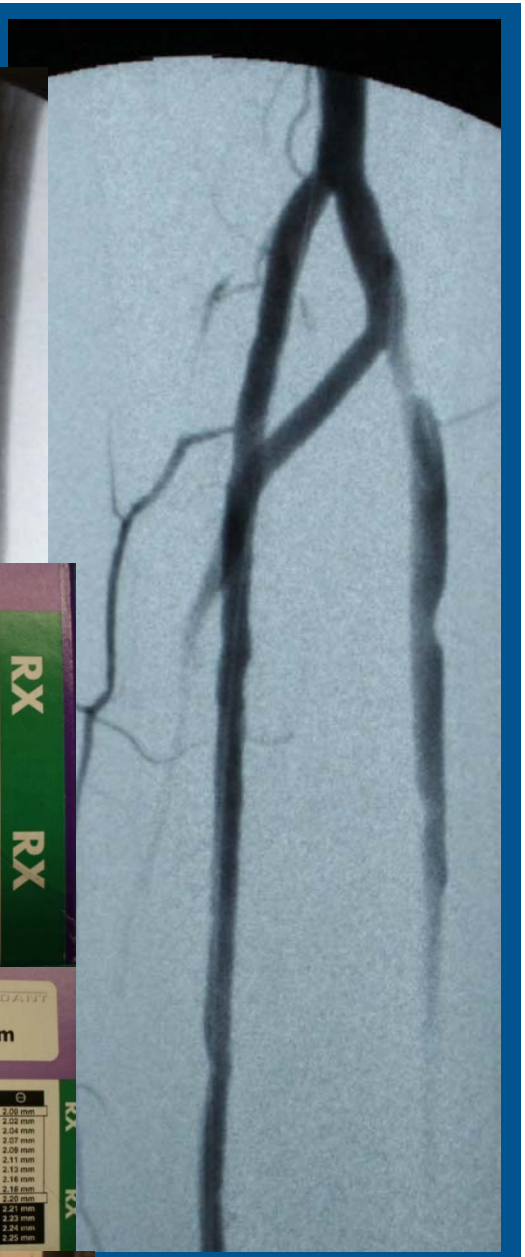

7) Use balloon expandable stents in the proximal tibial arteries and self-expanding stents in the distal arteries.

Balloon expandable

Self-expanding

Don’t know

8) Limb threat status is determined by the degree of ischemia,

but limb salvage is more dependent upon amount of foot damage and runoff.

9) Open more than one tibial if possible.

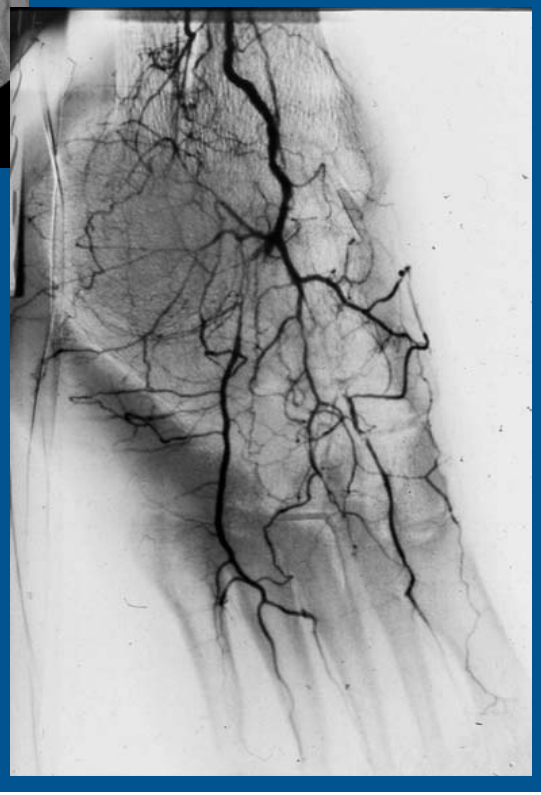

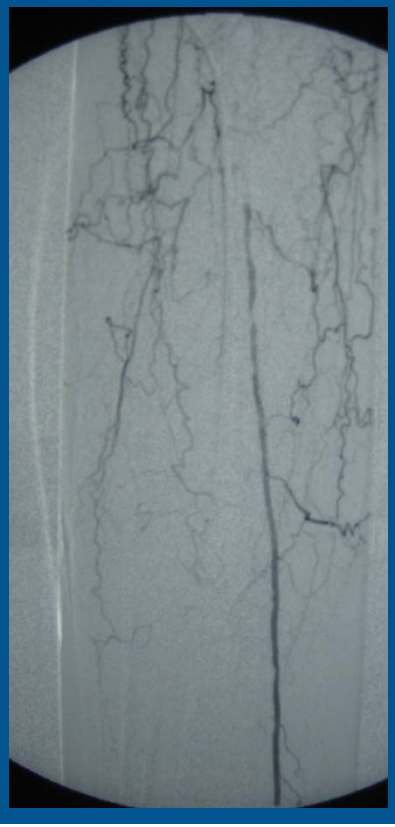

10) Do a bypass when runoff is poor and foot damage is severe.

THANK YOU!